

Mammography Education, Inc.

2010

BREAST SEMINAR SERIES

LÁSZLÓ TABÁR, M.D.,F.A.C.R (Hon) Course Director
Professor of Radiology

Detection *and* Diagnosis of Early Breast
Cancer Using *the* Multimodality
Approach

PHOENIX, AZ

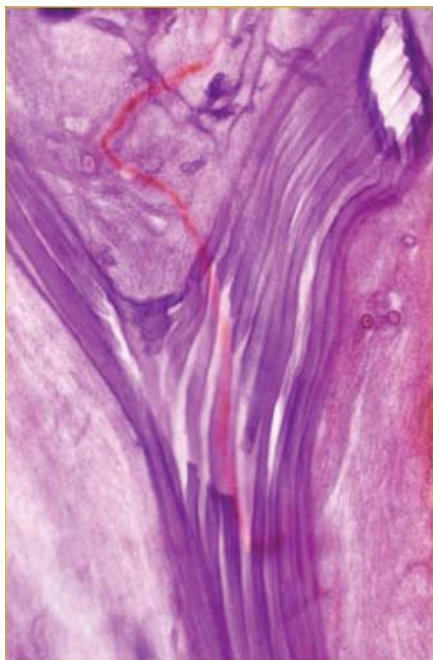Banner Good Samaritan Medical Center
Laura Dreier Breast Center
May 5-7, 2010

Designed for:

Radiologists • Surgeons • Pathologists
Gynecologists • Radiology Technologists

implications of mammography, MRI, breast ultrasound and
interventional methods in radiological and surgical practice

This course provides extensive knowledge about diagnostic breast
imaging, differential diagnosis of breast diseases, surgical management
and newest diagnostic technologies.



3D image of a milk duct



21 HOURS OF CATEGORY I CME CREDITS



2010
BREAST SEMINAR SERIES of MEI
Multimodality Detection and
Diagnosis of Breast Diseases

László Tabár, M.D.,
F.A.C.R.(Hon)
*Professor of Radiology
Course Director*

FACULTY



László Tabár, M.D., F.A.C.R. (Hon).
Course Director
*Professor of Radiology, University of Uppsala
School of Medicine, Sweden
Director, Department of Mammography, Falun
Central Hospital, Falun, Sweden*



Christophe Frouge, M.D., Ph.D.
*Medical Director of Breast Imaging
Valley Radiologists,
an affiliate of Southwest
Diagnostic Imaging
Phoenix Arizona*



2010
BREAST SEMINAR SERIES of MEI
Multimodality Detection and
Diagnosis of Breast Diseases

László Tabár, M.D.,
F.A.C.R.(Hon)
*Professor of Radiology
Course Director*



Mammography Education, Inc. is accredited by the Accreditation Council for Continuing Medical Education to sponsor continuing medical education for physicians. Mammography Education, Inc. designed these medical education activities for a maximum of **21 credit hours in Category I** of the Physicians' Recognition Award of the American Medical Association.

Each physician should claim only those hours of credit that he / she actually spent in the educational activity.

CREDITS

We would like to thank the sponsors for their support of the teaching seminars of Mammography Education, Inc (list of vendors will be presented at the beginning of the course)



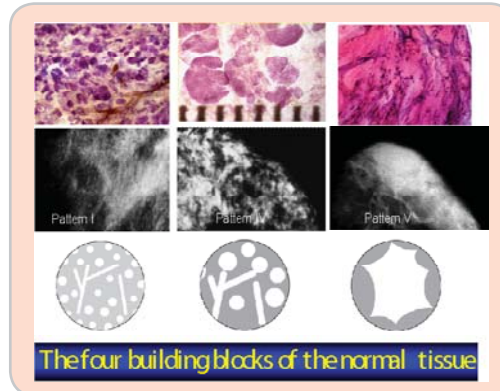
1st DAY Morning lectures between 8:30 AM and 12:00

8:30 INTRODUCTION FOLLOWED BY DIDACTIC LECTURES COVERING:

A NEW ERA in the DIAGNOSIS and TREATMENT of BREAST CANCER.
THE ISSUE of UNI- and MULTIFOCALITY - CLINICAL IMPLICATIONS

THE BASIS FOR EFFICIENT INTERPRETATION OF THE MAMMOGRAPHIC IMAGE

- Correlative 3-dimensional, subgross anatomy and mammography of the normal breast
- **The problem:** The variable appearance of the normal mammogram.
- **The solution:** classification into structural subtypes, mammographic parenchymal patterns, based on 3D/subgross histologic-mammographic correlation.
- **Result:** Increased confidence in reading a mammogram and finding subtle perceptual



Breaks at 10:00
and
at 11:00 AM

MAMMOGRAPHIC PARENCHYMAL PATTERNS

- Practical implication, problems and solutions. Mammographic patterns and the risk of developing breast cancer. Understanding the mammograms of dense breasts.

ASYMMETRIC DENSITIES ON THE MAMMOGRAM

- Didactic workup of asymmetric densities
 - normal breast tissue/focal fibrosis
 - non-specific asymmetric densities, MR images of diabetic mastopathy, PASH
 - definite pathologic lesions
- A suggested algorithm for the workup of asymmetric densities on the mammogram

12:00 L u n c h



1st DAY

Afternoon lectures between 1:00 PM and 4:30 PM

1:00 THE DIDACTIC LECTURE SERIES WILL COVER THE FOLLOWING TOPICS:

PRACTICAL APPROACH TO MR INTERPRETATION FOR MAMMOGRAPHERS - [Frouge C](#)

HYPERPLASTIC BREAST CHANGES - THE MAIN CAUSE OF DIFFERENTIAL DIAGNOSTIC PROBLEMS - [Tabar L](#), [Frouge C](#)

BENIGN CIRCULAR / OVAL SHAPED LESIONS - [Tabar L](#), [Frouge C](#)

- Cysts, fibroadenoma, papilloma, pyllodes tumors, galactocele, abscess
- Histology correlation with mammograms, MRI and clinical findings of benign lesions

BENIGN TYPE CALCIFICATIONS IN HYPERPLASTIC BREAST CHANGES, CAUSING DIFFERENTIAL DIAGNOSTIC PROBLEMS - [Tabar L](#), [Frouge C](#)

- Weddellites, slate-like particles, powdery/cotton ball-like calcifications

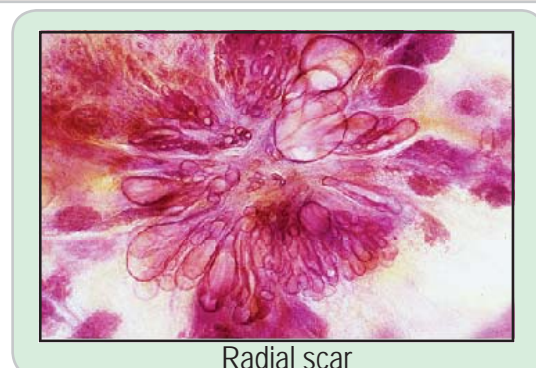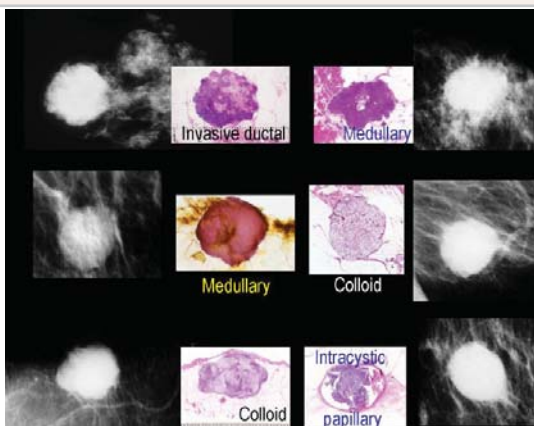
BENIGN RADIATING STRUCTURES on the mammogram - [Tabar L](#), [Frouge C](#)

- Radial scar. Traumatic (postsurgical) scar / fat necrosis / granular cell tumor
- Indications and contraindications of using preoperative percutaneous biopsy techniques

MALIGNANT CIRCULAR / OVAL LESIONS: clinical presentation, histology, mammographic and MRI appearance, breast ultrasound and outcome - [Tabar L](#), [Frouge C](#)

- Medullary cancer: one of the fastest growing breast cancers
- Mucinous and papillary cancers: unusual and special forms
- Metastasis to the breast

Breaks at 2:00
and
at 3:00 PM



Radial scar

4:30 End of Day 1



2nd DAY

Morning lectures between 8:30 AM and 12:00 PM

8:30 HOW TO FIND THE INVASIVE BREAST CANCER WHEN IT IS STILL SMALL . SCREENING COMBINED WITH AN ANALYTICAL APPROACH FOR THE DIFFERENTIAL DIAGNOSIS OF STELLATE/SPICULATED LESIONS

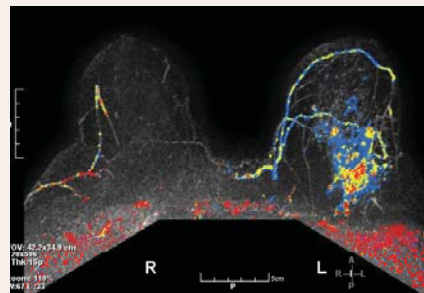
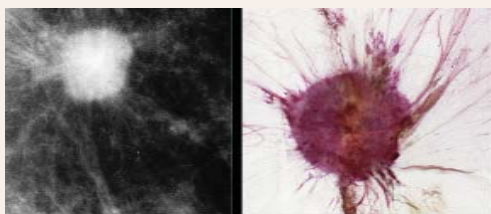
- A systematic method for viewing mammograms.
- Areas on the mammogram where most breast cancers will be found
- Viewing dense breasts
- Viewing relatively easy-to-read breasts

PRACTICE IN PERCEPTION OF SUBTLE, NON-CALCIFIED CANCERS

The role of hand-held ultrasound / 3D automated ultrasound / MRI in the detection and workup of the findings. The multimodality approach - [Tabar L, Frouge C](#)

- *Malignant stellate lesions*: clinical presentation, histology, mammographic/ MRI/ ultrasound appearance and outcome:
 - **invasive ductal carcinoma**, not otherwise specified (NOS): the most frequently occurring carcinoma. Multimodality case demonstrations
 - **tubular carcinoma**: the stellate tumor with the best outcome
 - sonographic and MRI correlation with the mammogram

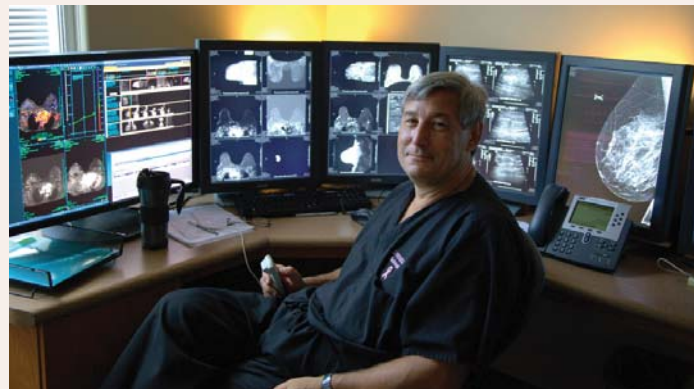Breaks at 10:00
and
at 11:00 AM



INDICATIONS FOR BREAST MR - [Frouge C](#)

30 min

12:00 Lunch





2nd DAY

Afternoon lectures between 1:00 PM and 4:30 PM

1:00 SCREENING COMBINED WITH AN ANALYTICAL APPROACH FOR THE DIFFERENTIAL DIAGNOSIS OF STELLATE/SPICULATED LESIONS - CONT.

- A systematic method for viewing mammograms.
- Areas on the mammogram where most breast cancers will be found
- Viewing dense breasts
- Viewing relatively easy-to-read breasts

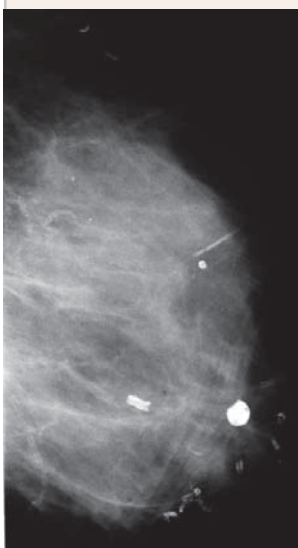
PRACTICE IN PERCEPTION OF SUBTLE, NON-CALCIFIED CANCERS.

The role of hand-held ultrasound / 3D automated ultrasound / MRI in the detection and workup of the findings. The multimodality approach.

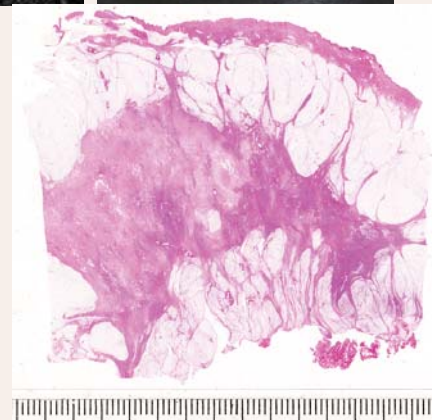
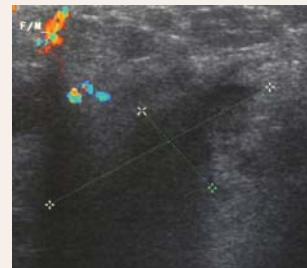
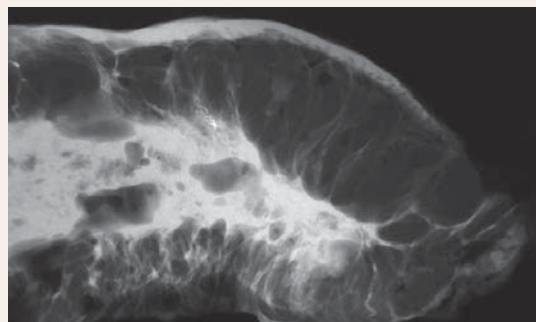
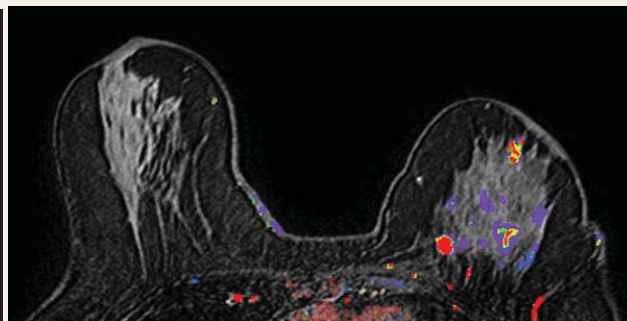
- *Malignant stellate lesions*: clinical presentation, histology, mammographic appearance and outcome:

Breaks at 2:00
and
at 3:00 PM

- **invasive lobular carcinoma**: the most deceptive and frequently missed cancer of the breast. The value of ultrasound and MRI in finding and diagnosis invasive lobular cancer subtypes. Case demonstrations - [Tabar L](#), [Frouge C](#)



Multimodality workup of a huge invasive lobular carcinoma



4:30 PM End of Day 2



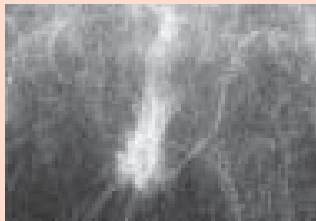3rd DAY Morning lectures between 8:30 AM and 12:00 PM

8:30 THE DIDACTIC LECTURE SERIES WILL COVER THE FOLLOWING TOPICS:

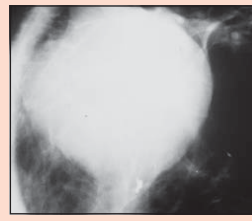
DESCRIPTION OF THE MAMMOGRAPHIC SIGNS OF *IN SITU* BREAST CANCER

- Categorization of **all abnormalities** commonly seen on the mammogram.
- Overview of the subtle mammographic signs of *in situ* carcinoma
- Every fourth DCIS case is detected by mammographic signs other than calcifications
- **Special forms of *in situ* carcinoma**
 - architectural distortion
 - dominant mass
 - cases detected by galactographic examination

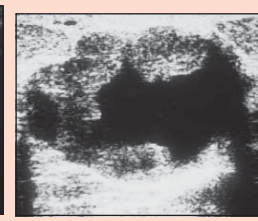
Breaks at 10:00
and
at 11:00 AM



Architectural distortion, *in situ* carcinoma

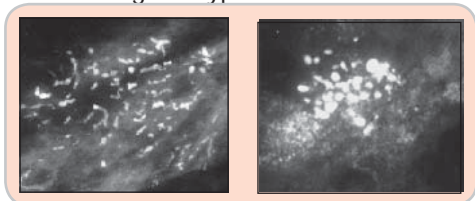


Dominant mass, *in situ* carcinoma



SCHEME FOR THE ANALYSIS OF MAMMOGRAPHIC CALCIFICATIONS - [Tabar L, Frouge C](#)

- Understanding the process producing **calcifications**
- The morphologic analysis of calcifications representing an aggressive carcinoma that must not be missed or undertreated: **poorly differentiated/high grade/Van Nuys Group 3 CIS**
- Practical aspects of management.
- Interactive evaluation and differential diagnosis of benign versus malignant type calcifications by course participants
- The role of MRI examination in demonstrating the extent of Gr 3 CIS and helping in treatment planning. Case demonstration



SCHEME FOR THE ANALYSIS OF MAMMOGRAPHIC CALCIFICATIONS

- The morphologic analysis of calcifications representing a less aggressive carcinoma: **intermediate grade/ moderately differentiated / Van Nuys Group 2 CIS**

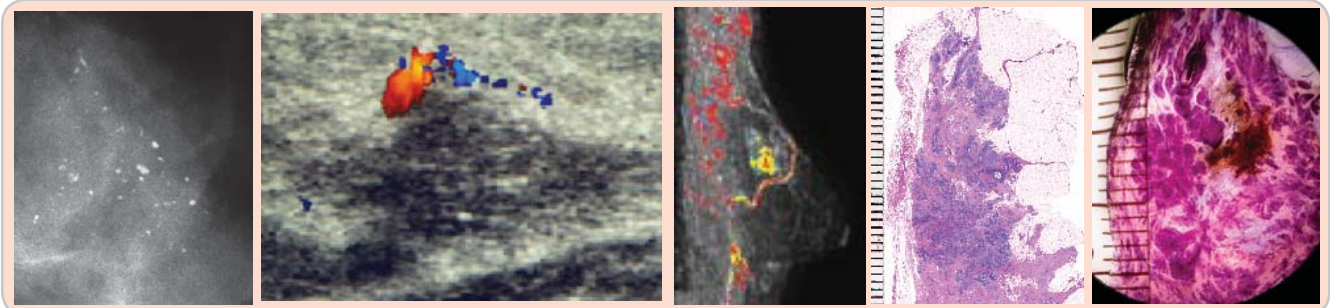
12:00 Lunch



3rd DAY Afternoon lectures between 1:00 PM and 4:00 PM

1:00 THE DIDACTIC LECTURE SERIES WILL COVER THE FOLLOWING TOPICS:

MAMMOGRAPHIC / 3-D HISTOLOGIC/ MRI CORRELATION of CASES with CRUSHED STONE LIKE CALCIFICATIONS and THEIR IMPACT on TREATMENT PLANNING - [Tabar L](#), [Frouge C](#)

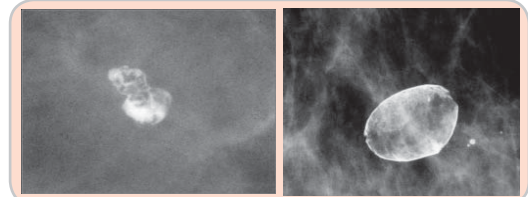


- The morphologic analysis of calcifications representing a less aggressive carcinoma: *well differentiated / Van Nuys Group 1 CIS*

BENIGN TYPE CALCIFICATIONS - LOCALIZED OUTSIDE THE GLANDULAR TISSUE

- Interactive evaluation and differential diagnosis of benign versus malignant type calcifications by course participants
- Assigning probability of malignancy to the various calcification subtypes
- Indications and contraindications for preoperative needle biopsy of calcifications
- Short-term follow up of calcifications: pitfalls
- The obviously benign type calcifications.

**Breaks at 2:00
and
at 3:00 PM**



LYMPHEDEMA OF THE BREAST - A DIFFERENTIAL DIAGNOSTIC CHALLENGE

- Didactic approach to the differential diagnosis of diseases leading to lymph stasis of the breast
- Regular follow-up of patients after breast cancer surgery. Postoperative and postirradiative changes with time

THE MALE BREAST. THE AUGMENTED BREAST. DISCUSSION

4:00 End of the course



2010
BREAST SEMINAR SERIES of MEI
Multimodality Detection and
Diagnosis of Breast Diseases

László Tabár, M.D.
Professor of Radiology
Course Director

For more information and
registration please contact:

Mammography Education, Inc.
4429 E. Spur Drive
CAVE CREEK, AZ 85331, USA

Phone: (480) 419 0227

Fax: (480) 419 0219

e-mail: info@mammographyed.com

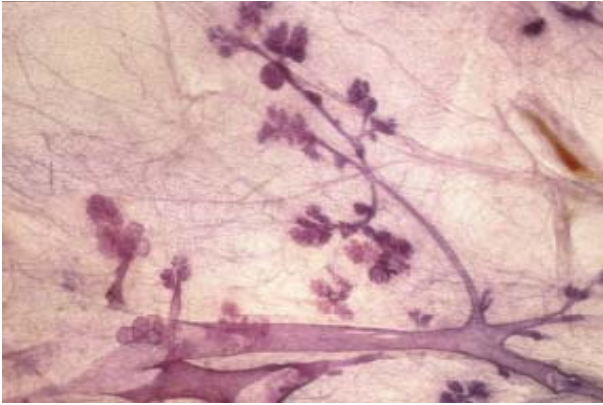
Internet: www@mammographyed.com

THE SCHEDULE IS SUBJECT TO CHANGE WITHOUT NOTICE AND
DOES NOT REPRESENT A COMMITMENT ON THE PART OF M.E.I.

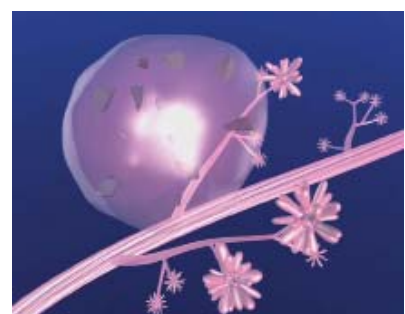
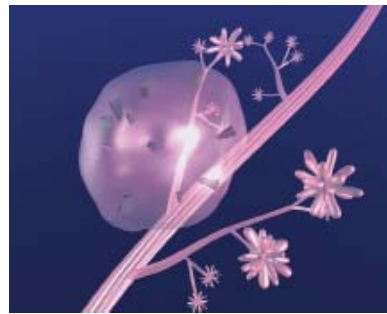
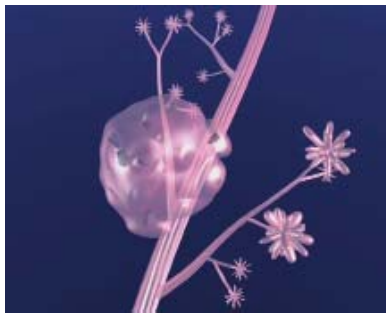

ALL RIGHTS RESERVED INCLUDING THE RIGHT OF REPRODUCTION
IN WHOLE OR IN PART OF ANY FORM

VISIT US ON THE INTERNET:
[HTTP://WWW.MAMMOGRAPHYED.COM](http://WWW.MAMMOGRAPHYED.COM)

COPYRIGHT ©



3-D histologic image of TDLUs



Computer simulation images of the development of Grade 2 *in situ* carcinoma within the TDLU. The lobule becomes gradually distended and deformed. Calcifications are formed within the necrotic debris and are seen on the mammogram as **crushed stone-like calcifications**.